

Original Article

Potential Ameliorative Effect of *Artemisia Absinthium* Supplement against Sodium Fluoride-Induced Prostatic Toxicity in Rats

Shakir Saleh, H¹*, Yahya Kraidi, S², Ali Mahdi, W³

1. Biology Department, College of Education for Pure Science, University of Thi-Qar, Nasiriyah, Iraq
2. Pharmacology Department, College of Pharmacy, Al-Muthanna University, Samawah, Iraq
3. College of Pharmacy, University OF Kerbala, Kerbala, Iraq

Received 16 December 2021; Accepted 16 January 2022
Corresponding Author: hazarsaleh@utq.edu.iq

Abstract

Prostate dysfunction is the most common condition among aged men, which causes adverse complications and may result in serious diseases. *Artemisia* has been studied since time immemorial in several studies all showing its ability in preventing and treating different diseases. However, so far there have been no studies focusing on the possible role of *Artemisia* in the protection of prostate histoarchitecture toxicity. Therefore, this study aimed to investigate the protective role of *Artemisia* in the amelioration of histological and hormonal depression affected by sodium fluoride (NaF). A total of 28 male adult Wistar rats were equally divided into four groups (n=7). Animals in the control group received normal saline. The second group received NaF by oral gavage at a dose of 12 mg/kg body weight (B.W.) three times a week. The third group received concurrent treatment with NaF at a dose of 12 mg/kg B.W. three times a week, as well as extraction of *Artemisia absinthium* at a dose of 100 mg/kg B.W. The fourth group was treated only with extraction of *Artemisia absinthium* at a dose of 100 mg/k B.W. After 60 days, B.W. and the absolute weight of the prostate were measured. Blood samples and tissues were collected for measuring testosterone, follicle-stimulating hormone, as well as luteinizing hormone concentration, conducting paraffin-embedded sections with hematoxylin, and eosin routine staining. The findings revealed that *Artemisia* supplement significantly increased body and absolute weight of prostate gland in the group treated by NaF. In addition, mitigating the histological changes throughout the restoration of all prostate components appeared nearly as normal structural tissue. Moreover, the height of glandular epithelium decreased, follicular lumen enlarged, dark secretion materials with homogeneity disappeared of invagination intraluminal, and normal stroma appeared in regular shape. All in all, the results of this study pointed out that *Artemisia* had a protective effect against NaF-influenced prostate toxicity via stabilizing male hormones, re-composing histoarchitecture, and returning abnormal biomorphic parameters to a nearly normal state.

Keywords: *Artemisia*, Histopathology, Prostate, Sodium fluoride, Toxicity

1. Introduction

The prostatic disorder could be considered a chronic condition that most aged men may encounter, which might be diagnosed as prostatitis or benign prostate hyperplasia (1). According to Zhong, Lin (2), 42% of men aging 40 to 50 years old and up to 90% of those over 70 years old face benign prostate hyperplasia

worldwide in different cultures and ethnicities. Essentially, prostate depression is manifested in several clinical signs and symptoms in a variety of ranges and degrees, such as painful pelvic, discomfort in urination, and sexual disorders (3, 4). Ultimately, the main form of this illness is chronic prostatitis which is classified into acute, chronic, and nonbacterial prostatitis.

Furthermore, it was found that 90% of all prostatitis cases are due to chronic nonbacterial prostatitis (5). Accordingly, many recent studies have referred to histopathology changes in the prostate, such as the collapse of the gland and fibrosis in the stroma, as well as the occurrence of inflammation signs even in the absence of infectious etiologies (6-8). Therefore, since the pathogenesis of prostatitis is related to inflammation and acts on the activation of leukocytes to induce free radicals throughout this pathway process, it is necessary to treat it with antioxidants (9-11). *Artemisia absinthium* is a common herbal medication in alternative medicine in the Middle East and Asia. According to several documents in herbal medicine, *Artemisia* is an anti-oxidative plant that has a high content of phytochemicals, including phenolic acids, flavonoids, flavonoid glycosides containing essential oil, and organic acids (12). It has been elucidated that *Artemisia* has effective pharmacophores in free radical scavenging action, as well as anti-inflammatory and antioxidant activity (13).

According to previous studies, fluoride exposure has several deleterious effects on the reproductive system (14-16). Therefore, this study aimed to investigate the possible ameliorative effect of *Artemisia absinthium* against oxidative stress induced by sodium fluoride (NaF) affecting the prostate in rats. There is still a lack of enough evidence to prove its effectiveness on male genital glands, such as the prostate organ, and thus, the target objective of this study is to disclose the ameliorative effect of *Artemisia absinthium* against the adverse effects of NaF-compromised male genital glands.

2. Materials and Methods

2.1. Animal Husbandry

In total, 28 male adult Wistar rats were used in this study, whose age and weight ranges were 12-14 weeks and 250-300 gm, respectively. All rats were fed with a standard diet and had added libitum access to water. Environmental conditions throughout the setting included a temperature of 20°C, humidity of 5%, as well as a 12-h light period.

2.2. Experimental Design

Adult male Wistar rats (n=28) were equally divided into four groups (n=7). Animals in the control group received normal saline. The second group received NaF by oral gavage at a dose of 12 mg/kg body weight (B.W.) three times a week. The third group received concurrent treatment with NaF at a dose of 12 mg/kg B.W. three times a week, as well as extraction of *Artemisia absinthium* at a dose of 100 mg/kg B.W. The fourth group was treated only with extraction of *Artemisia absinthium* at a dose of 100 mg/kg B.W. After 60 days, the animals' B.W. was measured again after the treatment. In addition, the testis weight was measured after euthanizing all rats with anesthetizing agents. Blood samples were taken before scarifying the animals for measuring testosterone, follicle-stimulating hormone (FSH), and luteinizing hormone (LH) concentration by the enzyme-linked immunosorbent assay technique using the ELISA kit (Monobind Inc. lake forest, CA, 92630, USA). After removing prostates, the tissue was immediately immersed into Bouin's fluid for fixation to prepare histological sections at 5- μ m thickness. Afterward, paraffin-embedded sections were handled and the sectioning proceeded to stain all slides with hematoxylin and eosin routine stain. Subsequently, prostate components were histologically examined to determine histopathological changes by using a light microscope (17). In addition, the histomorphometric parameters of the epithelial height, acinar luminal area, as well as the stromal area of the prostate, were measured and analyzed by using Image J software (18, 19).

2.3. Statistical Analysis

All data were represented as mean \pm SE and analyzed by the SPSS software (Version 21) by running the One-Way ANOVA test (Duncan test).

3. Results

The recorded data showed that B.W. and the absolute prostate weight in the animals of group 1 significantly reduced, compared to the control group (group 2) and group 3 (Table 1). The results also revealed that

Artemisia absinthium treatment effectively compensates for the adverse effects of NaF on prostate and body weight. Similarly, the recorded data showed that *Artemisia absinthium* has significantly reversed the induced reduction in the levels of FSH, LH, and testosterone in rats treated with NaF ($P \leq 0.05$), as illustrated in table 2.

Histological findings in the control group of rats show that prostate structures were normal (Figure 1) in the architectural organization, which was manifested in the glandular epithelium surrounding the prostate follicular lumen. Additionally, it contains colloid materials, which appeared as homogenous serous secretions. The acinar epithelium was composed of columnar cells resting on the basement membrane with interspersed basal cells between them. Sparse stroma diffused intra interstitial space between the tubules.

Meanwhile, prostatic epithelial cells underwent hyperplasia in the NaF-treated rats, and there was a remarked increase in intraluminal budding giving it a metaplasia figure 2. However, columnar cells turned into cuboidal or flattened shapes. Follicular lumen contained calcified and non-homogeneity secretion materials. This material disappeared in some prostatic follicles. Furthermore, prostatic follicles appeared in an irregular shape and underwent hypertrophy.

In *Artemisia* extraction-treated rats, the findings showed that all prostate components were restored and appeared nearly as normal structural tissues (Figure 3). The height of the glandular epithelium decreased, the follicular lumen enlarged, and the dark secretion materials were found with homogeneity. Moreover, the disappearance of the invagination intraluminal and the normal stroma appeared in a regular shape.

Table 1. Effect of Sodium fluoride and *Artemisia absinthium* supplement on body weight and absolute weight of prostate gland. Different letters refer to $P \leq 0.05$

Groups	Body Weight of Rats (g)	Prostate Weight (gm)
Control group	288.50±2.428 ^a	1.706±0.19 ^a
Sodium fluoride group (group 1)	182.93±2.868 ^c	0.7150±0.30 ^c
Sodium fluoride and <i>Artemisia</i> group (group 2)	230.17±3.045 ^{Ab}	1.098±0.022 ^{ab}
<i>Artemisia</i> group (group 3)	271.40±1.209 ^a	1.6820±0.140 ^A

Table 2. *Artemisia absinthium* modulating levels of FSH, LH, testosterone hormones in sodium fluoride-treated rats. Different letters refer to $P \leq 0.05$

Groups	FSH (mIU/ml)	LH (mIU/ml)	Testosterone (ng/ml)
Control group	2.988±0.0106 ^a	1.926±0.022 ^a	3.618±0.053 ^a
Sodium fluoride group (group1)	1.010±0.0203 ^c	0.293±0.038 ^c	0.699±0.250 ^c
Sodium fluoride and <i>Artemisia</i> group (group 2)	1.998±0.0140 ^{ab}	1.003±0.019 ^{ab}	2.012±0.0187 ^{ab}
<i>Artemisia</i> group (group 3)	3.074±0.0200 ^a	1.864±0.057 ^a	3.108±0.330 ^a

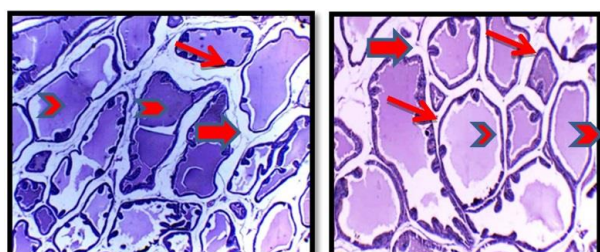


Figure 1. Photo-micrograph of normal histoarchitecture of prostate tissues. Columnar cells of glandular epithelium are shown by the thin arrow, secretion material by the head arrow, and interstitial stroma by the thick arrow. X (4×10) and X (10×10) are used in the left and right photo-micrograph, respectively

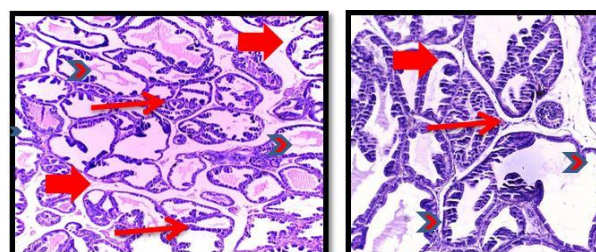


Figure 2. Photomicrograph of prostatic histoarchitectures in the sodium fluoride-treated rats. Columnar cells of glandular epithelium are shown by the thin arrow, secretion material by the head arrow, and the interstitial stroma by the thick arrow. X (4×10) and X (10×10) are used in the left and right photo-micrograph, respectively

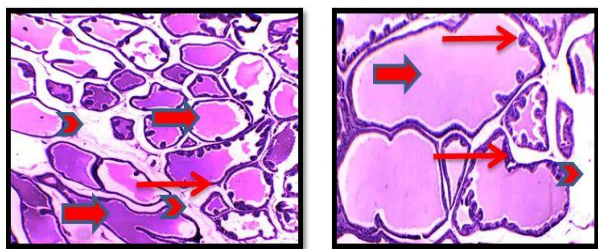


Figure 3. Photo-micrograph of prostatic histoarchitectures in *Artemisia* and sodium fluoride-treated rats. Columnar cells of glandular epithelium are shown by the thin arrow, secretion material by the head arrow, and the interstitial stroma by the thick arrow). X (4×10) and X (10×10) are used in the left and right photo-micrograph, respectively.

The highest number of epithelial cells was observed within prostate follicles in rats treated with NaF (29.17 ± 0.06). Additionally, compared to the control group (16.41 ± 0.37), it significantly increased in group 3 ($18.0.12 \pm 0.36$) and group 4 (16.41 ± 0.32), respectively (Figure 4). Meanwhile, a small acinar luminal area appeared in the group treated with NaF, while a large acinar luminal area appeared in the group treated with *Artemisia*, which was comparable to the control group, with their area measurements determined at 358.55 ± 2.09 , 216.76 ± 1.65 , and 302.32 ± 0.97 , respectively (Figure 5). In the case of stroma area measurement, there was a significant increase in *Artemisia*-treated rats, compared to the stroma area in rats treated with the NaF but not with the control group rats, with their stroma area being measured at 286 ± 1.77 , 139 ± 3.05 , and 248 ± 2.68 , respectively (Figure 6).

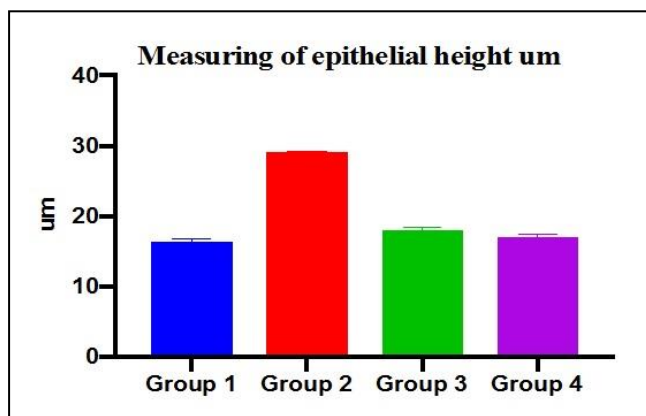


Figure 4. Mean±SE of epithelial heights in all study groups. Significant differences were determined at $P \leq 0.05$

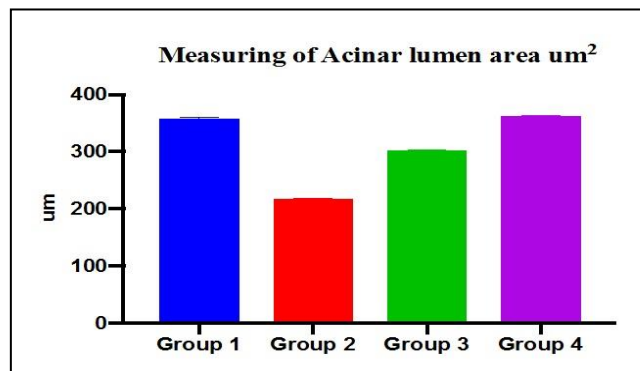


Figure 5. Mean±SE of acinar lumen area in all study groups. Significant differences were determined at $P \leq 0.05$

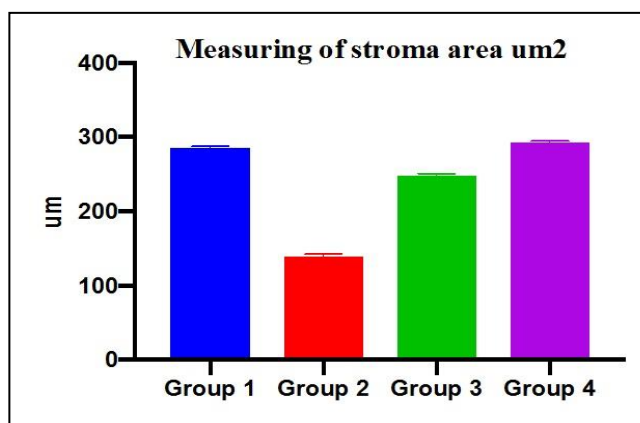


Figure 6. Mean±SE of the stromal area in all study groups. Significant differences were determined at $P \leq 0.05$

4. Discussion

The obtained findings of the present study obviously indicated that NaF insulted the structure and function of the prostate gland. Animals treated with NaF showed a significant decline in their body weight, which was attributed to the metabolic processes, such as glycolysis, synthesis of proteins, and anti-oxidative pathways. These changes, along with reduced food intake, caused a decrease in their B.W., thereby leading to the loss of prostate weight (7, 20, 21). On the other hand, NaF-treated rats showed an improvement in their B.W. during the treatment with the extraction of *Artemisia* since it contains high levels of protein, vitamins, as well as flavonoids (12, 13), and has a crucial role in the growth and enhancement of weight gain in general through reducing fluoride toxicity. In the same context, it maintained an absolute prostate weight.

The present study found a significant reduction in testosterone concentration due to the experimental fluoride toxicity, which was in agreement with a previous study showing that fluoride affected fertility by reducing testicular zinc levels causing the impaired activity of the angiotensin-converting enzyme (22, 23). Therefore, it is implied that this alteration in testosterone levels may also influence changes in the weight of the prostate gland (24). Accordingly, this study also referred to the decline in the level of FSH, as well as LH, which results from NaF and may affect the pituitary gland and result in the reduction of steroid biosynthesis (23). Consequently, NaF could affect the pituitary gland causing a reduction in the level of gonadotropin-releasing hormone (responsible for FSH and LH), leading to the reduction of steroid biosynthesis (8, 24). Therefore, the decline of testosterone levels in the NaF-treated group was proven in this study by the induced histological alteration of the prostate tissue structures, which revealed abnormal histological features. Previous reports confirmed that oxidative stress induced by free radicals plays a role in the pathogenesis of prostate dysfunctions as indicated by histopathological alteration (17, 19). In addition, this study focused on the investigation of abnormal histological and histomorphometric changes in rats treated with *Artemisia* extracts. It was found that the modulated histological features and the abnormal histomorphometric parameters caused by NaF were restored and ameliorated in the *Artemisia*-treated group, which was comparable to that in the control group. Moreover, it is well-established that *Artemisia absinthium* has antioxidant properties and antioxidative activity due to its extraction containing phenolic and flavonoids compounds, which acts a crucial role in cells protection against oxidative and deleterious effects. Subsequently, many studies have shown that *Artemisia absinthium* can reverse the adverse action in anemia and protect the liver and kidney from lead-induced toxicity (9, 12, 13). In the same context, histomorphometric findings in this study clarified that

the elevation in the epithelial height of fluoride-affected rats happened due to the decrease of testosterone, which causes the hyperplasia of the epithelial cells and increases their thickness. This finding was consistent with the findings of previous studies (7, 8, 17, 19). On the other hand, the *Artemisia* treatment group showed a decline in the epithelial height, which was comparable to the control group. The significant decrease of the acinar luminal area in the NaF-treated group was remarkable, compared to the *Artemisia* treatment group, which was consistent with the findings of a previous study conducted by Agrawal, Nahata (22) showing the projection of epithelial cells into the lumen of acinar tubules of the gland. However, the acinar luminal area increased in the *Artemisia* treatment group due to the extracts acting on the suppressed and controlled proliferation of the epithelial cells, leading to the significant disappearance of the epithelial height protrusion. Furthermore, secretion material was nearly restored to normal. It might be suggested that the action of *Artemisia* compounds has a role in the increase of prostate fluids, as well as the absolute prostate weight. The stromal area narrowing within prostatic interstitial tissue revealed a significant reduction in the NaF group, as opposed to the other two groups (i.e., *Artemisia* and control), which manifested a large expansion of the stromal area due to the involvement of different types of cells and fibers, such as myofibers and collagen, respectively. It is known that the interstitial tissue of the prostate gland contains a specific stroma composed of fibroblasts and smooth muscle cells (17). That can explain the ability of *Artemisia* extraction to recompose stroma connective tissue, which is consistent with the results of a previous study by El-Din and Fattah (18) observing stromal expansion with the amount of collagen composition within the interstitial stroma. To the best of the present researchers' knowledge, this study could be regarded as the first study disclosing that *Artemisia* supplement can reverse histopathological and histomorphometric changes associated with prostate gland dysfunction due to the

NaF effect in animal models. Furthermore, *Artemisia* extraction supplement acts on modulating three male hormonal stability (FSH, LH, and testosterone) after being affected by the NaF. Consequently, it may be recommended as a protective or alternative treatment for mild to moderate prostatic disorder.

Authors' Contribution

Study concept and design: H. S. S.

Acquisition of data: S. Y. K.

Analysis and interpretation of data: S. Y. K.

Drafting of the manuscript: H. S. S.

Critical revision of the manuscript for important intellectual content: W. A. M.

Statistical analysis: W. A. M.

Administrative, technical, and material support: H. S. S.

Ethics

All protocols of experimental animals were followed according to the Authorized Guidelines of Care and Use of Laboratory Animals in the College of Education for Pure Science, University of Thi-Qar, Nasiriyah, Iraq. This study was approved by the Ethics Committee of the University of Thi-Qar for animal research.

Conflict of Interest

The authors declare that they have no conflict of interest.

Acknowledgment

We acknowledge the support of the College of Education for Pure Science, University of Thi-Qar (Nasiriyah, Iraq) in the current study.

References

- Barkin J, Roehrborn CG, Siami P, Hailot O, Morrill B, Black L, et al. Effect of dutasteride, tamsulosin and the combination on patient-reported quality of life and treatment satisfaction in men with moderate-to-severe benign prostatic hyperplasia: 2-year data from the CombAT trial. *BJU Int.* 2009;103(7):919-26.
- Zhong X, Lin J, Zhou J, Xu W, Hong Z. Anti-proliferative effects of qianliening capsules on prostatic hyperplasia in vitro and in vivo. *Mol Med Rep.* 2015;12(2):1699-708.
- Krieger J, Ross S, Riley D. Chronic prostatitis: epidemiology and role of infection. *Urology.* 2002;60(6):8-12.
- Nickel JC, Shoskes DA, Wagenlehner FM. Management of chronic prostatitis/chronic pelvic pain syndrome (CP/CPPS): the studies, the evidence, and the impact. *World J Urol.* 2013;31(4):747-53.
- Khan FU, Ihsan AU, Khan HU, Jana R, Wazir J, Khongorzul P, et al. Comprehensive overview of prostatitis. *Biomed Pharmacother.* 2017;94:1064-76.
- Akdere H, Oztekin I, Arda E, Aktöz T, Turan FN, Burgazli KM. Analgesic effects of oligonol, acupuncture and quantum light therapy on chronic nonbacterial prostatitis. *Iran Red Crescent Med J.* 2015;17(4).
- Said MM, Bosland MC. The anti-inflammatory effect of montelukast, a cysteinyl leukotriene receptor-1 antagonist, against estradiol-induced nonbacterial inflammation in the rat prostate. *Naunyn Schmiedebergs Arch Pharmacol.* 2017;390(2):197-205.
- William FP, Russa DA. *Prunus africanus* Herbal Extracts Reverse and Ameliorate the Histological and Histomorphometric Changes in Testosterone-induced Benign Prostate Hyperplasia Rat Models. *Tanz J Sci.* 2021;47(3):1184-94.
- Msaada K, Salem N, Bachrouch O, Bousselmi S, Tammar S, Alfaify A, et al. Chemical composition and antioxidant and antimicrobial activities of wormwood (*Artemisia absinthium* L.) essential oils and phenolics. *J Chem.* 2015;2015.
- Saleh HS, Ali HN. Tocotrienol Mitigating Adverse Effect of Doxorubicin on Pancreas Tissue in Male Rats. *J Adv Biomed Pathobiol Res.* 2015;5(2):23-31.
- Saleh HS, Al-Kayat ES. Modulation Male Fertility in Diabetic Rats by Allicin Administration. *J Edu Pure Sci.* 2017;7(1).
- Li S, Zhou S, Yang W, Meng D. Gastro-protective effect of edible plant *Artemisia argyi* in ethanol-induced rats via normalizing inflammatory responses and oxidative stress. *J Ethnopharmacol.* 2018;214:207-17.
- Ahuja A, Yi Y-S, Kim M-Y, Cho JY. Ethnopharmacological properties of *Artemisia asiatica*: A comprehensive review. *J Ethnopharmacol.* 2018;220:117-28.

14. Chinoy N, Sorathia H, Jhala D. Fluoride+ aluminium induced toxicity in mice testis with giant cells and its reversal by vitamin C. *Fluoride*. 2005;38(2):109-14.
15. Khriachtchev L, Pettersson M, Runeberg N, Lundell J, Räsänen M. A stable argon compound. *Nature*. 2000;406(6798):874-6.
16. Sebert J, Richard P, Mennecier I, Bisset J, Loeb G. Monofluorophosphate increases lumbar bone density in osteopenic patients: a double-masked randomized study. *Osteoporos Int*. 1995;5(2):108-14.
17. Peehl DM, Sellers RG. Induction of smooth muscle cell phenotype in cultured human prostatic stromal cells. *Exp Cell Res*. 1997;232(2):208-15.
18. El-Din WAN, Fattah IOA. The potential curative and preventive effects of garlic on testosterone-induced benign prostatic hyperplasia in orchietomized rats. *Rom J Morphol Embryol*. 2019;60(1):145-58.
19. Shin IS, Lee MY, Ha HK, Seo CS, Shin H-K. Inhibitory effect of Yukmijihwang-tang, a traditional herbal formula against testosterone-induced benign prostatic hyperplasia in rats. *BMC Complement Altern Med*. 2012;12(1):1-7.
20. Gacci M, Vignozzi L, Sebastianelli A, Salvi M, Giannesi C, De Nunzio C, et al. Metabolic syndrome and lower urinary tract symptoms: the role of inflammation. *Prostate Cancer Prostatic Dis*. 2013;16(1):101-6.
21. Hao P, Ma X, Cheng X, Ba Y, Zhu J, Cui L. Effect of fluoride on human hypothalamus-hypophysis-testis axis hormones. *Wei Sheng Yan Jiu*. 2010;39(1):53-5.
22. Agrawal M, Nahata A, Dixit VK. Protective effects of *Echinops echinatus* on testosterone-induced prostatic hyperplasia in rats. *Eur J Integr Med*. 2012;4(2):e177-e85.
23. Littarru GP, Tiano L. Bioenergetic and antioxidant properties of coenzyme Q 10: recent developments. *Mol Biotechnol*. 2007;37(1):31-7.
24. Popoola B, Ashefor O, Akanni O, Adaramoye O. Biochemical, hormonal and histological changes in prostate of Wistar rats following long term streptozotocin-induced diabetes mellitus. *Niger J Physiol Sci*. 2017;32(1):75-84.