

A Study on Histopathologic Changes in Chicken Following Intravenous Inoculation with Avian Influenza Virus A/Chicken/Iran/259/1998(H9N2)

Hablolvarid^{*1}, M.H., Sohraby Haghdoost, I.,² Pourbakhsk, S.A.³ and Gholami, M.R.¹

1. Pathology Dept., Razi Vaccine & Serum Research Institute, P.O.Box 11365-1558, Tehran, Iran

2. Pathology Dept., Faculty of Tehran University, Tehran, Iran

3. Avian Diseases Research and Diagnosis, Razi Institute

Received 6 Feb 2003; accepted 28 May 2003

Summary

To determine the type, severity and frequency of gross, histopathologic changes and tissue tropism of avian influenza virus (AIV) a group of twenty, 5-week-old chickens (hatched from SPF eggs) were inoculated intravenously (IV) with type A AIV [A/Chicken/Iran/259/1998(H9N2)]. Another twenty chickens were inoculated IV with sterile chorioallantoic fluid (CAF). Tubulointerstitial nephritis and pancreatitis were the most frequent specific histopathologic changes. Influenza nucleoprotein was demonstrated in renal tubule epithelium and in acini of pancreas/foci of necrosis in both organs. The virus was localized in cytoplasm and nuclei of proximal/distal tubule epithelium. Common nonspecific histopathologic changes were lymphoid and reticuloendothelial cell hyperplasia in spleen, leukocyte cell infiltration in myocardium and lymphocyte infiltration in liver. The results indicate that the low pathogenic AIV isolate was epithiotropic in chicken.

Key words: chicken, avian influenza virus, low-pathogen, histopathology

Introduction

Avian influenza (AI) outbreaks in commercial chickens and turkeys are characterized by the sign of respiratory distress; decrease egg production and

* Author for correspondence. E-mail: Hablolvarid@yahoo.com

mortality rates that range up to almost 100%. Isolation of a non-highly pathogenic (n-HPAI) subtype H9N2 AIV was reported from Iran (Pourbakhsh *et al* 2000). Although some of the variation in disease severity can be attributed to pathogenicity differences among the infecting viruses, field evidence shows that a variety of often poorly defined host and environmental factors also play an important role in determining the outcome of infection (Alexander 1987, Brugh 1996). Earlier pathogenesis studies revealed that low-pathogenic AIVs are nephrotropic following intravenous inoculation while; following intratracheal or intranasal inoculation they are pneumotropic (Swayne *et al* 1994).

The purpose of the present study was to determine the type, severity and frequency of gross, histopathologic changes and tissue tropism in some of chicken's tissues following intravenous inoculation of Iranian AIV isolate.

Materials and Methods

Virus. The first passage of A/Chicken/Iran/259/1998(H9N2) was used. 0.2ml of 1:10 dilution ($10^{9.1}$ EID₅₀) in chorioallantoic fluid (CAF) was inoculated intravenously in chickens in treated group.

Experimental design. Forty 5-week-old chickens hatched from SPF eggs (Valo, Lohman, Germany) were randomly divided in two equal groups. Both groups were housed in same condition in two separate places. All chickens were provided feed and water *ad libitum*. All the birds were weighed and bled for detection of specific antibodies against the H9 subtype of AIV, Newcastle disease virus (NDV), infectious bronchitis virus (IBV) and infectious bursal disease virus (IBDV). The treated group was subsequently inoculated with the AIV isolate in CAF. The control group was received sterile CAF on the same manner. Five chickens from each group were randomly sampled on days 1, 3, 6 and 10 postinoculation (PI). They were weighed and bled again. Then they were humanely sacrificed (euthanatized) and necropsied, and gross lesions were recorded. Samples of different tissues including

lung, trachea, heart, liver, pancreas, duodenum, jejunum, thymus, spleen, brain, cecal tonsil and bursa of fabricius were collected for virus isolation, histopathology and immunohistochemistry studies. The isolation and identification of AIV were done according to Pearson *et al* (1987).

Serology. In order to find out the presence of specific antibodies against AIV, IBV, IBDV and NDV pre and postinoculation sera were tested. Hemagglutination inhibition (HI) test was used for detection of NDV and AIV antibodies. However, the commercial ELISA kits (Pro Flok® IBV Elisa Kit and Pro Flok® IBDV Elisa Kit) were applied for IBV and for IBDV antibodies.

Histopathology. Tissue sections were fixed for 24-28h in 10% neutral buffered formalin solution. The tissues were routinely processed to paraffin blocks, sectioned at 5µm, deparaffinized and stained with hematoxylin and eosin (H&E). The criterion of Swayne & Slemons (1995) was used for evaluation of the histopathological lesions. In this way lesions were categorized as specific (i.e., necrosis and inflammation) and nonspecific (i.e., lymphoid hyperplasia, lymphoid atrophy, lymphocyte depletion and lymphocytic cuffing).

Immunohistochemical detection of viral antigen. Immunohistochemical technique was performed in Italy (Istituto zooprofilattico sperimentale delle venzie-Padova, Italy) used to detect the influenza nucleoprotein in infected cells. A monoclonal antibody prepared against the nucleoprotein of AIV was provided by Dr. Swayne (USDA, Athens, GA, USA).

Results

Clinical findings. Control chickens didn't show any sign of illness. In infected chickens the signs of disease including depression and decrease activity, decrease feed consumption, ruffle feathers and diarrhea became apparent on day 2 PI. Between days 2 and 3 PI three infected chickens died.

Gross necropsy findings. Control chickens lacked gross lesions. The most frequent gross lesions in infected chickens were abnormal kidney (63%), decrease size of the bursa of fabricius (10%) and splenomegaly (5%). Generalized swelling and accentuated lobular pattern or multifocal elevated nodules were the most common kidney lesions on day 3 PI (Figure 1).

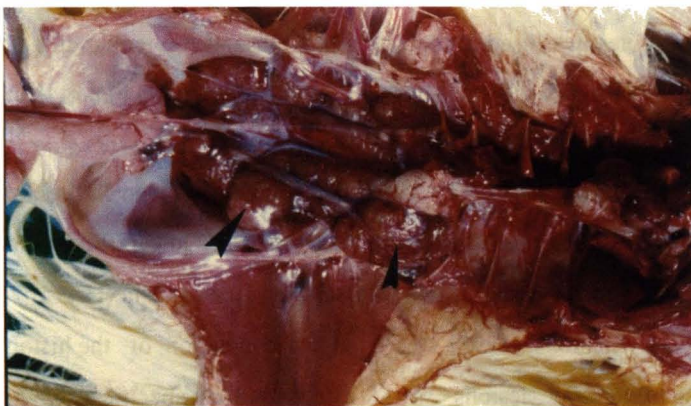


Figure 1. Swollen kidney with multifocal elevated nodules (arrows) in chicken inoculated IV with AIV H9N2 10 days PI

Serological findings. There was no evidence of specific antibodies against AIV, IBV, IBDV and NDV in pre and postinoculation of control chickens. The presence of specific antibody against AIV, but not others, was detected in treated group on days 6 and 10 PI.

Virus isolation. After three passages no AIV was isolated from visceral organs, lung and trachea of the control chickens while virus was easily recovered from visceral organs of infected chickens at the first passage. The virus was isolated from trachea and lung on days 1, 3 and 6 PI at the first passage and on day 10 PI on second passage. All of the isolated viruses had showed positive reactions by HA test. Moreover, in AIV HI test hemagglutination activity of all isolated viruses was inhibited.

Histopathology. In the control chickens no histopathologic changes were found in all organs. Data related to infected chicken were summarized in table 1. The spleen had the highest frequency of histopathologic changes among lymphoid tissues. Mild to moderate (few and more obvious changes, respectively) reticuloendothelial cell hyperplasia was present on days 3, 6 and 10 PI, moreover, on days 6 and 10 PI number and size of lymphoid follicles increased in some samples. Necrosis and inflammation were not seen. Mild to moderate atrophy of lymphoid follicles in the bursa (days 3 and 10 PI) was observed but necrosis of lymphoid cells or inflammation was not seen. In none of virus inoculated chickens on days 1-10 PI, no histopathological changes were observed in microscopic examination of thymus and cecal tonsils.

Table 1. *Organ histopathology and immunohistochemistry data in chicken inoculated intravenously with AIV H9N2*

Tissue	Frequency of changes (%)	Predominant lesions type	Category	Nucleo-protein
Kidney	75	Necrosis, nephritis	Specific	+
Pancreas	53.3	Necrosis, pancreatitis	Specific	+
Spleen	46.7	Lymphoid and RE hyperplasia	Non-specific	-
Liver	38.8	Lymphocyte infiltration	Non-specific	-
Heart	31.5	Lymphocyte infiltration	Non-specific	-
Bursa	20	Lymphoid atrophy	Non-specific	-
Lung	16.7	Lymphocyte infiltration	Non-specific	-

Acute heterophilic tubulointerstitial nephritis with necrosis of tubule epithelium was identified on kidney samples on day 3 PI (Figures 2, 3). On day 6 PI, lymphocytic tubulointerstitial nephritis with increase in number and size of lymphocytic follicles and aggregates was present. There were some tubular casts in some of samples. In one case foci of heterophilic tubulointerstitial nephritis were found. On day 10 PI chronic-inactive and less commonly, and chronic-active tubulointerstitial nephritis were found. Both types were composed of multiple foci of fibrosis, atrophic tubule, dilated tubules with eosinophilic casts, foci of calcification,

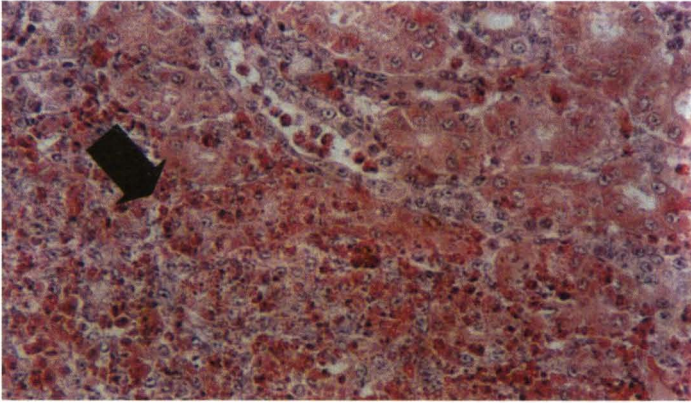


Figure 2. *Tubulointerstitial nephritis-necrosis and heterophil infiltration arrow H&E (400)*

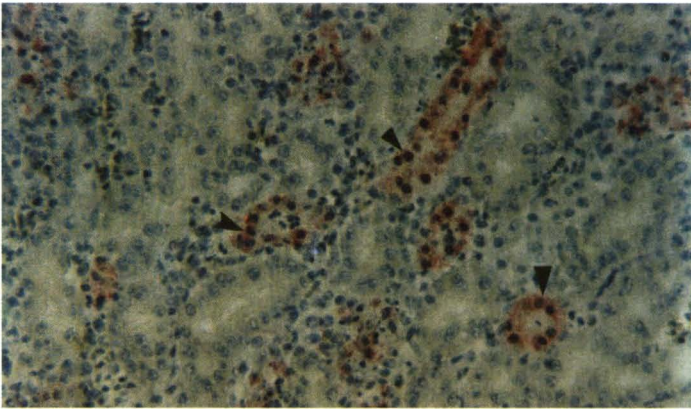


Figure 3. *Arrows points to localization sites of virus in renal tubules ICH (400)*

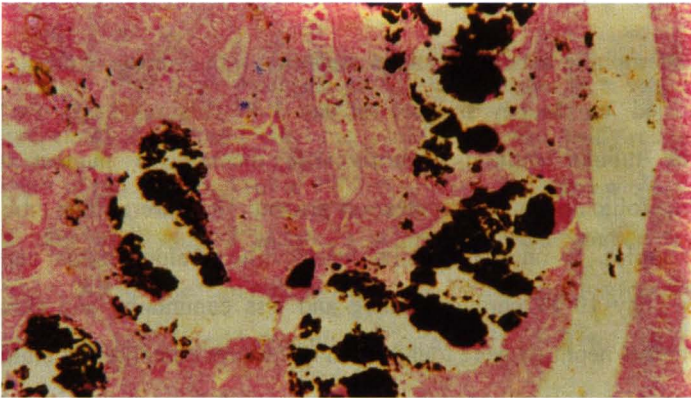


Figure 4. *Chicken kidney. Black areas are calcification foci Von kassa (200)*

increased number and size of lymphocytic follicles and lymphoid aggregates. In special staining (Von kossa) foci of calcification were observed as black areas (Figure 4).

In alimentary system there were not any pancreatic lesions on day 1 PI. However, acute pancreatitis with severe acinar necrosis and heterophils infiltration was present on day 3 PI (Figures 5, 6, 7). On day 6 PI chronic pancreatitis with necrosis, infiltration of lymphocytes and few heterophils, and in one sample fibrosis was seen. On day 10 PI, chronic pancreatitis with diffuse fibrosis, acinar dilation, lymphocyte infiltration and few heterophils were present. Presence of heterophils in chronic pancreatic areas indicated that the lesion was active.

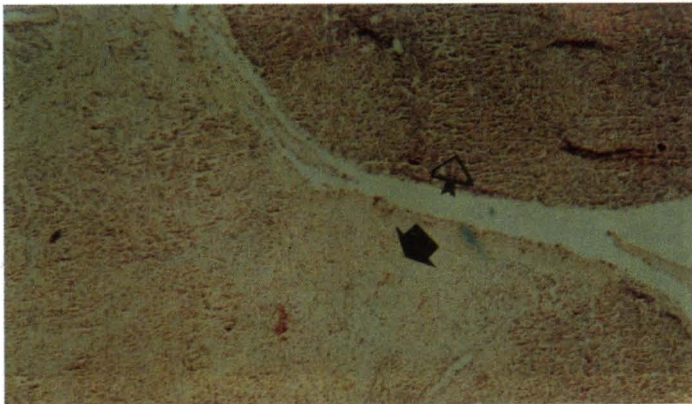

Figure 5. Acute pancreatitis. Severe necrosis (black arrow) and normal acinies (bright arrow)
H&E ($\times 100$)

No lesion was identified in liver of chickens on day 1 PI. On days 3, 6 and 10 PI, mild to moderate lymphocyte infiltration in parenchyma and near vessels was present; moreover, some samples had hepatocyte degeneration. In all of infected chickens, from day 1-10 PI, no histopathological changes were observed in duodenum and jejunum. There were no histopathological changes in lungs and tracheas of infected chickens on days 1, 6 and 10 PI. However, mild infiltration of lymphocytes in submucosa of secondary bronchi was present on day 3 PI. No lesion



Figure 6. *Chicken pancreas. Red spots are virus localization sites (nucleoprotein) IHC (x100)*




Figure 7. *Chicken pancreas. Arrow points to virus localization sites (nucleoprotein) IHC (x400)*

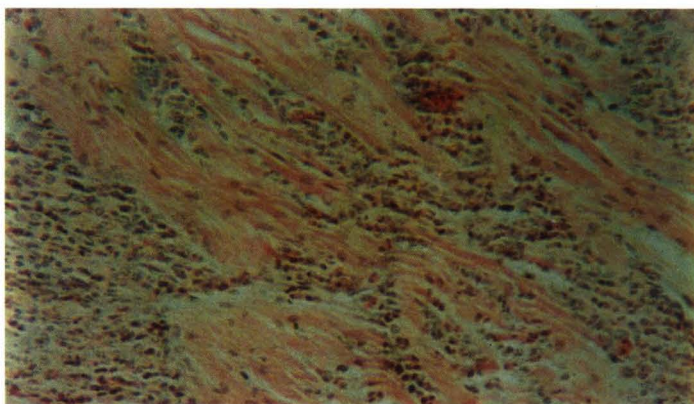


Figure 8. *Chicken heart. Leukocytes infiltration between myocardial cells H&E (x400)*

was identified in brains of infected chickens, but heart showed mild myocardial degeneration. On day 6 PI multifocal leukocytic infiltration in the myocardium of some chicken were observed (Figure 8).

Viral antigen distribution. Influenza viral nucleoprotein (AVN) was not found in all tissues of control chickens. In infected chickens AVN was identified in the kidney and pancreas. The nucleoprotein was consistently localized to necrotic tubule epithelium within area of heterophilic tubulointerstitial nephritis and foci of acinar necrosis in pancreas. Specially, AVN was identified within nuclei and cytoplasm of necrotic renal tubule epithelium/pancreatic anici.

Discussion

In this study the most specific histopathologic lesions were tubulointerstitial nephritis and pancreatitis. By observation of virus localization sites concurrent with histopathological changes in kidney the lesions were as the results of direct influence of virus replication in renal tubules (Swayne & Slemons 1990, Slemons *et al* 1990a, b). Tubulointerstitial nephritis, especially its multifocal cortical distribution and location in proximal tubules was the same as infectious bronchitis and avian infectious nephritis. There are several reports about kidney lesions in chickens infected with low and highly pathogenic AIVs (Mutinelli *et al* 2000, Slemons *et al* 1990 and 1991, Laudert 1993). Swayne & Slemons (1990) by IV inoculation of A/Mallard/Ohio/184/86 to 5-week-old SPF chickens observed the sign of mottled and elevated nodules on the surface of kidney. In histopathological examination multifocal heterophilic tubulointerstitial nephritis and fibrosing interstitial nephritis with atrophy of tubules, focal and diffuse interstitial lymphocyte infiltration observed. The presence of multifocal heterophilic tubulointerstitial nephritis indicated that low pathogenic AIV (LPAIV), water fowl origin, could induced acute and active chronic nephritis in chickens, moreover, the kidney has the potential for survival of the virus. In present study heterophilic tubulointerstitial

nephritis were observed after day 3 PI. Previous histopathological and immunohistochemical findings of Swayne *et al* (1990 and 1992) on LPAI showed that the necrosis of renal tubule, especially proximal tubules, were associated with viral replication. Mildly pathogenic AIV can not persist in the kidney of chicken and thus does not continue to produce necrosis of renal tubule epithelium (Slemons & Swayne 1992). Swayne *et al* (1994) reported that necrosis of renal tubules followed by renal failure can be as the cause of death. In agreement with Slemons *et al* (1990a, b) the results of our study on foci of lesions and virus isolation indicate that the kidney is a proper tissue for replication of H9N2 influenza virus.

In this study after day 3 PI, the sign of acute pancreatitis with diffuse necrosis, and chronic pancreatitis were observed. Localization of viral nucleoprotein in pancreatic lesions indicate the direct effects of virus on pancreas, which in time causes enzymes deficiency, necessary for digestion, followed by growth retardation in chickens (Silvano *et al* 1997, Shinya *et al* 1995).

No lesion except some lymphocyte infiltrations under secondary bronchi on day 3 PI was observed in the study. This showed that in IV route, no obvious lesion produce in respiratory system. On the other hand, lack of lymphocyte necrosis in primary and secondary lymphatic organs showed that the chicken lymphocyte was not targeting organ for H9N2 AIV. Significant changes were observed in spleen, bursa, liver and heart and most changes were lymphoid and reticuloendothelial hyperplasia. According to Swayne & Slemons (1995) these changes could be as the result of host immune response (T and B-lymphocytes) for elimination of foreign antigens. However, were not specific and also indication of direct or indirect effects of AIV H9N2. Atrophy of bursa was similar to non-specific response to endogenous glucocorticoide (Khodakaram Tafti & Marjanmehr 1997) and infiltration of lymphocytes in myocardium was similar to mild non-specific immunologic reaction. Absence of lymphocyte necrosis in primary and secondary lymphatic organs indicated that AIV H9N2 is neither lymphotrop nor lymphocide. The lesions of

interstitial nephritis with necrosis in renal tubules, pancreatitis with acinar necrosis and observation of foci of viral localization in these organs indicate the epitheliotropic nature of AI H9N2. Moreover in IV route kidney and pancreas are the target organs. Swayne & Slemons (1984) by inoculation of three LPAIVs to 5-week-old chickens showed that those viruses were nephrotropic in IV route while, in IT and IN routes they are pneumotropic. Presence of foci of nucleoprotein localization in nuclei and cytoplasm of renal tubules and in necrotic sites of pancreas and histopathological changes of mentioned tissues showed that these lesions produced by direct effects of AIV. Other studies (Shalaby 1994, Slemons 1992 and 1995, Swayne 1992) revealed that kidney, pancreas and oviduct are the major localization sites following IV inoculation of LPAIVs.

In conclusion, we can claim that A/Chicken/Iran/259/1998(H9N2), an Iranian AIV isolate, is a low-pathogenic virus, which in IV inoculation has tissue tropism to kidney and pancreas of chickens, and could produce sever damage in these organs.

Acknowledgments

We thank to Mrs. F. Taleblo and Mr. A. Habibpour for their technical assistance, thanks also for all staffs of Pathology department of Razi Vaccine & Serum Research Institute.

References

Alexander, D.J. (1987). Criteria for definition of pathogenicity of avian influenza viruses. *Proceeding 2nd International Symposium of avian Influenza*. U.S. Animal Health Association, Richmond, VA. Pp:228-245.

Brugh, M. (1996). Pathogenicity of three avian influenza virus for leghorn hens of different ages. *Avian Diseases* 40:727-728.

Khodakaram Tafti, A., Marjanmehr, S.H. (1997). *Avian Histiopathology* (C. Ridel, Ed.), Shiraz University Publication 258 (Translated to Persian).

Mutinelly, F., Capua, I., Bozza, M.A., Grossele, B. and Furlantini, V. (2000). Comparative intravenous pathogenicity for turkey and chickens of low-pathogenic avian influenza A/Tu/Italy/3675/99. *Proceeding of the 3rd international symposium on turkey disease*. Pp:146-170.

Pearson, J.D., Senne, D.A. and Panigraphy, B. (1987). Diagnostic procedures for avian influenza. *Proceeding of the second international symposium on avian influenza. United States Animal Health Association, Athens, GA*. Pp:222-227.

Pourbakhsh, S.A., Khodashenas, M., Kianizadeh, M. and Goodarzi, H. (2000). Isolation and identification of influenza virus H9N2 subtype. *Archives of Razi Institute* 51:27-38.

Shalaby, A.S., Slemons, R. D. and Swayne, D.E. (1994). Pathological studies of A/Chicken/Alabama/7395/75(H4N8) influenza virus in specific pathogen free laying hens. *Avian Pathology* 24: 623-632.

Shinya, K., Anokura, T., Shimada, A., Silvano, F.D., Umemura, T. and Ostuki, K. (1995). Pathogenesis of pancreatic atrophy by avian influenza A virus infection. *Avian Pathology* 24:623-632.

Silvano, F.D., Kanata, Y., Takeuchi, M., Shimada, A., Otsuki, K. and Umemare, T. (1997). Avian influenza A virus induced stunting syndrome like disease in chickens. *Journal of Veterinary Medicine* 59:205-207.

Slemons, R.D., Swayne, D.E. (1990a). Replacation of a water fowl–origin influenza virus in the kidney and intestine of chicken. *Avian Diseases* 34: 227-284.

Slemons, R.D., Locke, L.N., Sheerer, M.G., Duncan, R. M., Hishaw, V. S. and Easterday, B.C. (1990b). Kidney lesions associated with mortality in chickens inoculated with water fowl influenza viruses. *Avian Diseases* 34: 120-128.

Slemons, R.D., Swayne, D.E. (1992). Nephrotropic properties demonstrated by A/Chicken/Alabama/75(H4N8) following intravenous challenge of chickens. *Avian Diseases* 36:926-931.

Slemons, R.D., Swayne, D.E (1995). Tissue tropism and replicative properties of water fowl-origin influenza viruses in chickens. *Avian Diseases* 39:521-527.

Swayne, D.E., Slemons, R.D. (1984). Comparative pathology of a chicken origin and two duck origin influenza virus isolated in chickens, the effect of route of inoculation. *Veterinary Pathology* 31: 237-245.

Swayne, D.E., Slemons, R. D. (1990). Renal pathology in specific-pathogen-free chickens with a water fowl-origin type A influenza virus. *Avian Diseases* 34:285-294.

Swayne, D.E., Slemons, R.D. (1992). Evaluation of the kidney as a potential site of avian influenza virus persistence in chickens. *Avian Diseases* 36:937-944.

Swayne, D.E., Radin, M.J., Hoepf, M.T. and Slemons, R. D. (1994). Acute renal failure as the cause of death in chickens following intravenous inoculation with avian influenza virus A/Chicken/Alabama/7395/75(H4N8). *Avian Diseases* 38:151-157.

Swayne, D.E., Slemons, R.D. (1995). Comparative pathology of intravenously inoculated wild duck and turkey origin type A influenza virus in chickens. *Avian Diseases* 39:74-84.