

Isolation and Identification of Infectious Laryngotracheitis Virus from Commercial Flocks of Iran Using Various Techniques

**Ebrahimi^{*1}, M.M., Pourbakhsh, S.A.,² Shahsavandi, S.,² Momayez, R.²
and Gholami, M.R.³**

*1. Poultry Vaccines Research & Production Dept., Razi Vaccine & Serum Research Institute,
P.O.Box 11365-1558, Tehran, Iran*

2. Avian Diseases Research & Diagnosis Dept., Razi Institute

3. Pathology Dept., Razi Institute

Received 21 Jul 2003; accepted 14 Oct 2003

Summary

The clinical signs and postmortem findings including respiratory system distress and lesions in upper respiratory tract were observed in 17 commercial layer flocks from different parts of Iran. Laryngotracheal tissues from the affected birds with suspected infectious laryngotracheitis (ILT) were examined for detection of the causative agent using virus isolation (VI), agar gel immunodiffusion (AGID), histopathology (HP), and polymerase chain reaction (PCR). 12 (70.5%) of the samples were formed typical pocks on chorioallantoic membrane of embryonated specific pathogen free eggs in VI method. By AGID test 11 (64.7%) of the samples were detected as ILT virus (ILT.V) that gave clear lines with hyperimmune ILT serum. Of the samples 7 (41.1%) were illustrated lesions characteristics of ILT including infiltration of inflammatory cells and syncytia formation. In 14 (82.3%) of the samples ILT.V was detected by PCR. The high positive percentages of the PCR indicate that the technique is applicable in rapid diagnosis of ILT for its accuracy, sensitivity and specificity.

Key words: Infectious laryngotracheitis virus, isolation, identification, Iran

^{*} Author for correspondence. E-mail: emm@rvsri.com

Introduction

Infectious Laryngotrachitis (ILT) is an important respiratory disease of chicken caused by gallid herpes virus 1 of the family *Herpesviridae* (Murphy *et al* 2000). The disease is characterized by conjunctivitis, ocular discharge, sneezing, rales, nasal exudate, swollen of infaraorbital and nasal sinuses. In sever cases gasping, dyspnoea and death through asphyxation may occur (Jordan 1993). The morbidity rate of ILT, up to 100%, is depending onto virulence of strain and immune status of the flock (Hanson & Bagust 1997, Hughes *et al* 1991a). ILT virus (ILTV) may cause high mortality and decreased egg productions, both in broiler and in layer (Jordan 1990). Mortality is highly variable, ranging from 0.1% to 70% (Hanson & Bagust 1997).

Recently, mild to moderate form of the disease is reported from Iran by Iranian Veterinary Organization. Commonly, various laboratory diagnostic techniques have been used for detection of ILTV including virus isolation in either embryonated chicken eggs or in cell culture, serological tests and histologic evidence of tracheal epithelium (Hanson & Bagust 1997). Recently, molecular identification such as polymerase chain reaction (PCR) has been applied to identification of ILTV (Tripathy 1998, Jones 2000). In this study the isolation and identification of ILTV from the suspected flocks using various techniques were discussed. Beside applying of current diagnostic techniques we developed a PCR DNA amplification method that is used for the location of small amounts of ILTV DNA in infected tissues of birds to introduce an accurate, sensitive and specific detection system for diagnosis of ILTV isolates.

Materials & Methods

Sample. Clinical signs and postmortem findings of the affected birds were recorded. Under minimal contamination condition, the laryngotrachral tissues were dissect and a portion of the trachea was used for histopathology. The other portion

was homogenized in 1ml of phosphate buffer saline as inocula for virus isolation. The samples stored at -70°C until use.

Virus isolation (VI). Homogenized samples after thawed, diluted approximately 1/10 in nutrient broth containing penicillin, streptomycin and gentamicin, and agitated vigorously. The resulting suspension was centrifuged and then 0.2ml of supernatant fluid was inoculated onto the dropped chorioallantoic membrane (CAM) of six 10-to-12-day-old specific pathogen free (SPF) embryonated chicken eggs. The eggs were incubated at 37°C for 4-6 days. The CAMs harvested and examined for pock formation. The neutralization test with monospecific antiserum was used for confirmation of the isolated viruses. The isolation of an agent virus has been confirmed the diagnosis of infectious disease so, in this study VI test was considered as a golden standard.

Agar gel immunodiffusion (AGID). The gel was made with 1.5% Nobel agar (Difco Laboratories, Detroit, Michigan, USA) containing 8% sodium chloride and 0.1% Merthiolate-aspreservative in distilled water. The molten agar was poured into Petri dish. When the agar was set, a pattern of wells punched in agar dish. The hyperimmune serum was pippted into the central wells, while the surrounding wells were filled with suspect virus samples under test. Dishes were incubated in a humid atmosphere at 37°C , and examined 48h later with oblique illumination for lines of precipitation.

Histopathology (HP). Segments of trachea of infected chickens, approximately 3cm caudal to larynx, were placed in neutral buffer formalin and submitted for routine processing. Sections were cut at $3\mu\text{m}$ and stained with hematoxylin and eosin.

PCR technique. 1) *DNA extraction.* A $100\mu\text{l}$ aliquot from homogenized samples were incubated for 4h at 56°C with $100\mu\text{l}$ of lysis buffer (1% sodium dodecyl sulfate in 10mM Tris and 1mM EDTA) and $200\mu\text{g/ml}$ of proteinase K (Roche, Germany). After incubation, DNA was extracted with phenol (1:1) followed by a

phenol:chloroform (1:1) and a chloroform extraction. Absolute ethanol was used to precipitate DNA in the presence of 1/10 volume of 3M sodium acetate (pH5.2) for 20min at -20°C and pelleted by centrifugation at 11,000rpm (Eppendorf 5417R; Brinkmann Instruments, Westbury, NY) for 20min. Pelleted DNA was washed by 70% ethanol and resuspended in 10 μl double-distilled water for use in subsequent PCR amplification reactions.

2) *PCR procedure.* The primer set was used to amplify a 458-bp ILTV DNA fragment: forward, 5'-TAC AGC AGC AAC AAC CGG AG-3'; reverse, 5'-TGG CCT AGC TGT ACT GGA AC-3' according to Clavijo & Nagy (1997). All reactions were run with a total volume of 50 μl in a thermocycler (Mastercycle Eppendorf). Optimal concentrations of primers, Mg^{2+} and deoxynucleoside triphosphates (dNTPs), and optimal annealing temperature were determined by PCR assays using purified ILTV DNA (modified live ILT vaccine, Razi Institute). The reaction mix contained 1 μl DNA sample, 100pmol of each primer (TIB MOLBIOL, Germany), 0.5mM of each dNTP (Roche, Germany), 3mM MgCl_2 , 1mM KCl, 2.5U of *Taq* DNA polymerase (Roche, Germany), and 1XPCR buffer. The cycling parameters were an initial denaturation at 94°C for 2min, followed by 30 cycles of denaturation at 94°C for 30sec, annealing at 58°C for 40sec, and extension at 72°C for 30sec. The final cycle was followed by an extension at 72°C for 1min. The negative controls included an uninfected CAM sample and avian poxvirus isolates, which processed in the same manner as the test virus strains. The positive controls included two vaccine ILTV strains were considered. Following amplification, 10 μl of each PCR reaction sample was electrophoresed in a 1.5% agarose gel along with controls and a 100-bp DNA molecular weight marker (Fermentas, Germany) and visualized with ethidium bromide (0.5 $\mu\text{g/ml}$). Results were recorded using Polaroid film and a 302-nm UV light source. To test the specificity of the PCR, amplification reactions were performed with DNA from adenovirus, fowl poxvirus and Marek's disease virus. The specificity and sensitivity of the PCR were evaluated and

compared with VI test. In addition, CAM sample from uninfected embryonated egg was tested by PCR as a negative control.

Results

The affected birds had shown clinical signs including sneezing, coughing, oral and nasal discharge, gasping and rales, spasm and hemorrhagic conjunctivitis with various morbidity and mortality. Hemorrhage in tracheas and larynxes with mucus and caseous yellowish exudates were observed in postmortem examination. Several diagnostic procedures were performed on the laryngotracheal samples taken from 17 different flocks to determine the ILTV. In virus isolation method 12 (70.5%) of the samples were formed typical pocks on CAM of embryonated SPF eggs after one or two passages (Figure 1). Moreover, the isolated viruses were neutralized by monospecific antiserum. Of the ILTV suspected isolates, 11 (64.7%) isolates were serologically identified as ILTV in which showed clear lines with hyperimmune ILT serum in AGID test (Figure 2).

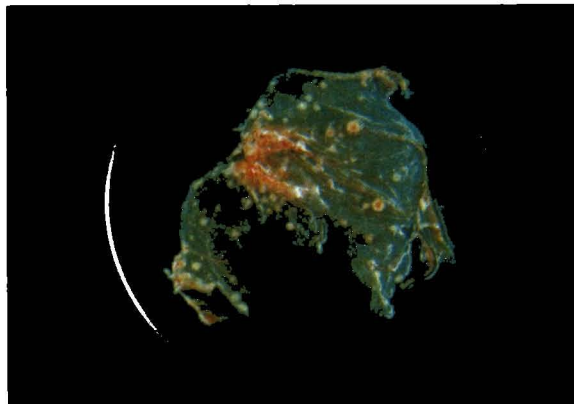


Figure 1 *Typical appearance of the lesions of ILTV including several pocks in CAM after 4-6 days postincubation*

Amplification products, regardless of the primer set used, were obtained from suspected ILTV DNA and a band related to the DNA fragment of the 458-bp was

seen in 14 (82.3%) of the samples. All of the positive results in other techniques were also identified as ILTV by PCR. Both the specificity and sensitivity of the PCR were calculated 100%. The results of detection of ILTV were summarized in table 1.




Figure 2. Precipitin patterns of ILT hyperimmune serum (center well), isolated field ILTV's (outer wells 2-5), positive control (1) and negative control (6)

Table 1. Results of detection of ILTV in field specimens by various techniques

No. Sample	Technique			
	VI	AGID	IIP	PCR
1	+	+	-	+
2	+	-	-	+
3	-	-	-	+
4	+	+	+	+
5	+	+	+	+
6	-	-	-	-
7	+	+	+	+
8	-	-	-	-
9	+	+	+	+
10	+	+	-	+
11	+	+	-	+
12	+	+	-	+
13	-	-	-	-
14	+	-	+	+
15	+	+	-	+
16	-	-	+	+
17	-	-	+	+
Positive/ Total	12/17 (70.5%)	11/17 (64.7%)	7/17 (41.1%)	14/17 (82.3%)

Amplification of the expected size from all ILTV tested, indicating that the primer sequences are conserved in all viruses. The specificity of the PCR procedure to amplify the 458-bp fragment was examined by using DNA templates isolated from adenovirus, fowl poxvirus and Marek's disease virus. The DNA of the viruses and also the negative control did not give visible bands. Data are shown in figure 3.

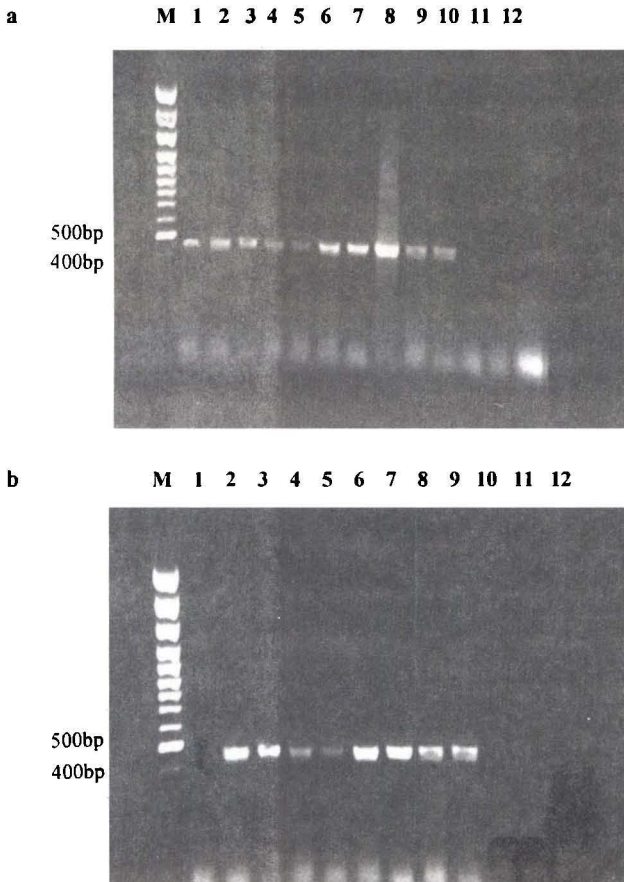


Figure 3. Agarose gel electrophoresis and ethidium bromide staining of PCR products amplified from DNA. a) Lane M shows the 100-bp molecular weight marker DNA, lanes 1-10: field isolate ILTVs, lane 11: adenovirus, lane 12: Marek's disease virus and lane 13: fowl pox virus. b) Lane M shows the 100-bp molecular weight marker DNA, lane 1: negative control, lane 2: ML live ILT vaccine virus and lanes 3-9: field isolate ILTVs

7 (41.1%) of the samples were illustrated lesions characteristics of ILT including infiltration of inflammatory cells, eosinophilic intranuclear inclusion bodies and syncytia formation (Figure 4).

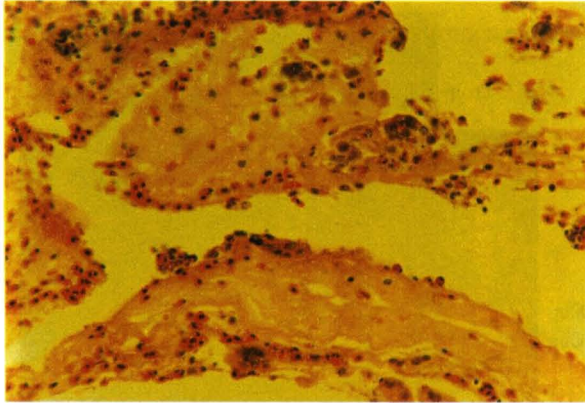


Figure 4. *Histopathological smear of infected trachea with ILTV consists of multinucleated giant cells (syncytial formation) with eosinophilic intranuclear inclusion bodies and infiltration of inflammatory cells*

Discussion

For diagnosis of ILT, laboratory assistance as other avian respiratory pathogens can cause similar clinical signs and lesions was required. Laboratory diagnosis may be achieved based on virus isolation, serology tests, and detection of ILTV DNA and also intranuclear inclusion bodies in infected tissues (Tripathy 1998). In this study we are detected the ILTV in field samples by different methods. Several studies on the use of the techniques for the detection and diagnosis of ILTV have been published (Williams *et al* 1994, Abbas & Andreasen, Jr 1996, Alexander & Nagy 1997). Each of them used demonstrated something different, and had distinct advantages and disadvantages.

VI is a sensitive test especially in the samples, which were taken in primary stages of the infection. Moreover, determination of the virus titer in the original sample and also study of the new isolation of field virus are the advantages of VI method.

Possible bacterial contamination in tracheal samples and their rapid growth on embryonated egg at incubation time is a problem can be interfered with VI method. Time-consuming and need to several passages in appearance of pocks, due to low level of infectious virus or high concentration of toxic material in the sample that may mask pock or even kill the embryos are additional difficulties of detecting ILTV by the method.

Although AGID is a simple and inexpensive test for detecting of ILTV but it can not possess high sensitivity especially when small amount of virus was there in the tissue sample (Bagüst *et al* 1986).

Demonstration of ILTV in 41.1% of samples indicates that HP is less sensitive than other techniques. Microscopic changes vary with the stage of the ILT disease. Multinucleated giant cells or syncytia and eosinophilic intranuclear inclusion bodies are the specially findings that observed in early stage of the infection (Vanderkop 1993, York & Fahey 1988). Diagnosis of ILT based on demonstration of the inclusion bodies in tissues is a highly specific method when compared with VI, but it's sensitivity is poor and also requires pathological expertise (Guy *et al* 1992).

The PCR method was the most sensitive, detecting highly positive percent from all of samples. The DNA amplification indicates the presence of two 20bp sequences, 458bp apart (Clavijo & Nagy 1997). In fact the positive results were achieved with DNA of ILTV in a primer set used. The positive result or detected ILTV may be primary infecting virus or it may represent low titers of latent virus that has recrudesced and is being shed from trachea (Williams *et al* 1994). In this study difference between positive results achieved by VI and PCR techniques may be due to low level of infectious virus and/or high sensitivity and specificity of the PCR. PCR facilitates amplification of a target sequence and offers several advantages over current diagnostic methods: viruses need not be viable prior to their detection by PCR; the technique possesses high sensitivity and specificity capable of detecting target DNA in a complex mixture so the generate state of the tissue and/or

presence of other viruses or bacteria do not interfere with the final result; and it is rapid and versatile. Small amounts of virus shed from either previously infected or vaccinated birds can be detected by DNA amplification (Hughes 1991b, Williams 1992). Despite the sensitivity and specificity of PCR however, some tissue and blood components can inhibit its enzymatic reaction that fails to diagnosis.

In the present study, the current diagnostic methods for detecting ILTV are described. Data clearly reveal that the PCR is an accurate, sensitive and specific detection system for ILTV. More studies should aim at increasing the detection sensitivity by applying the additional primer sets and at comparing pathogenic or nonpathogenic strains of ILTV.

Acknowledgment

This research is supported by grant from Ministry of Jihad-e-Agriculture No. 78-0430117000-01.

References

- Abbas, F., Andreasen, Jr., J.R. (1996). Comparison of diagnostic tests for infectious laryngotracheitis. *Avian Diseases* 40:290-295.
- Alexander, H.S., Nagy, E. (1997). Polymerase chain reaction to detect of laryngotracheitis virus in conjunctival swabs from experimentally infected chickens. *Avian Diseases* 41:646-653.
- Bagust, T.J., Calnek, B.W. and Fahey, K.J. (1986). Gallid-1 herpesvirusinfection in the chicken. 3. Reinvestigation of the pathogenesis of infectious laryngotracheitis in acute and early post-acute respiratory disease. *Avian Diseases* 30:179-190.
- Clavijo, A., Nagy, E. (1997). Differentiation of infectious laryngotrachities virus strains by polymerase chain reaction. *Avian Diseases* 41:241-246.

- Guy, J.S., Barnes, H.J. and Smith, L.G. (1992). Rapid diagnosis of infectious laryngotracheitis using a monoclonal antibody-based immunoperoxidase procedure. *Avian Pathology* 21:77-86.
- Hanson, L.E., Bagust, T.J. (1997). Laryngotracheitis. In: B.W. Calnek, H.J. Barends, C.W. Beared, M.W. Reid and H.W. Yoder, Jr (Eds.) *Diseases of Poultry* (10th edn.). Pp:527-539. Iowa State University Press, Ames, IA.
- Hughes, C.S., Gaskell, R.M., Bradbury, J.M., Jordan, F.T.W and Jones, R.C. (1991a). Study of field outbreaks of avian infectious laryngotracheitis in England and Wales. *Veterinary Record* 129:258-260.
- Hughes, C.S., Williams, R.A., Gaskell, R.M., Jordan, F.T.W., Bradbury, J.M., Bennett, M. and Jones, R.C. (1991b). Latency and reactivation of infectious laryngotracheitis vaccine virus. *Archives of Virology* 121:213-218.
- Jones, R.C. (2000). Avian infectious laryngotracheitis. In: *Office International des Epizooties, World Organization for Animal Health* (4th edn.). Pp:711-717. Paris, France.
- Jordan, F.T.W. (1993). Infectious laryngotracheitis. In: J.B. McFerran and M.S. McNulty (Eds.). *Virus Infection of Birds*. Pp:19-35. Elsevier Science Publishers B.V. Amsterdam, The Netherlands.
- Jordan, F.T.W. (1990). Infectious laryngotracheitis (ILT). In: F.T.W. Jordan (Ed.). *Poultry Diseases* (3rd edn.). Pp:154-158. W.B.Saunders Co., London, UK.
- Murphy, F.A., Gibbs, E.P.J., Horzinek, M.C. and Studdert, M.J. (2000). Herpesviridae. In: F.A. Murphy *et al* (Eds.) *Veterinary Virology* (3rd edn.). Pp:301-325. Academic Press. California, USA.
- Tripathy, D.N. (1998). Infectious laryngotracheitis. In: *A Laboratory Manual for the Isolation and Identification of Avian Pathogens* (4th edn.). Pp:111-115. The American Association of Avian Pathologists.
- VanderKop, M. (1993). Infectious laryngotracheitis in commercial broiler chickens. *Canadian Veterinary Journal* 34:185.

- Williams, R.A., Savage, C.E. and Jones, R.C. (1994). A comparison of detect electron microscopy, virus isolation and a DNA amplification method for the detection of avian infectious laryngotrachities virus in field material. *Avian Pathology* 23:709-720.
- Williams, R.A., Bennett, M., Bradbury, J.M., Gaskell, R.M., Jones, R.C. and Jordan, F.T.W. (1992). Demonstration of sites of latency of infectious laryngotracheitis virus using polymerase chain reaction. *Journal of General Virology* 73:2415-2420.
- York, J.J., Fahey, K.J. (1988). Diagnosis of infectious laryngotracheitis using a monoclonal antibody ELISA. *Avian Pathology* 17:173-182.