

ISOLATION OF *ACTINOMYCES BOVIS* IN PSEUDO-ALVEOLAR  
HYDATID CYSTS\*

*I. Mobedi*,\*\* *J. Vandyoosefi*,\*\*\* *A. Talebi-Najad*,\*\*\*\* and *J. Akbarzadeh*\*\*\*\*\*

SUMMARY

Occasionally seen in beef liver is a pseudo - Olveolar type of hydatid cyst which enlarges by budding and is «strile». During the period April, 1975, to January 1981 nine of ten such cysts collected from the Tehran abattoir were found to be infected with *Actinomyces bovis*. It is speculated that *A. bovis* stimulates the hydatid cyst to expand by normal budding and to invade surrounding tissue, somewhat in the manner of the alveolar hydatid of *Echinococcus multilocularis*.

INTRODUCTION

Cysts resembling those of *Echinococcus multilocularis* occur in farm animals in different parts of the world . Such infections have been reported in cattle in U. S. A., (Magath, 1965) , and IRAN (Afshar et al 1969) and in Pigs, cattle and sheep in Russia (Sadikov, 1967) . These cysts have been referred to as pseudo - alveolar by Cameron and Webster, 1962, and as *Echinococcus multilocularis veterinarius* by others (senk, Brglez 1966). Macroscopically, they so closely resemble the larvae of *E. multilocularis*, that some authors believe them to belong to Q subspecies of *E. multilocularis* which develops in sheep and cattle, (Rausch,

---

(\*) Supported in part by funds of the school of public Health and Institute of public Health Research, University of Tehran, and by the Ministry of Health and plan Organization.

(\*\*) Parasitology Department, School of public Health P. O. Box 1310, Tehran, IRAN.

(\*\*\*) Microbiology Department, Razi Institute, IRAN (P.O. Box 656 )

(\*\*\*\*) Ministry of Health, Tehran, IRAN.

(\*\*\*\*\* ) Department of Laboratory animals, Razi Institute, IRAN.

Nelson, 1963, Rausch, 1967, Schults, 1962) . However, Sadikov ( 1967 ) failed to infect puppies and kittens by feeding them pseudo - alveolar cysts obtained from sheep, cattle and pigs. Moreover reports indicate that farm ruminants are not susceptible to infection with *E. multilocularis*, ( vogel. 1957, Gorina, 1960, Safronov, 1963, Kurashvili and Gurchiani, 1965, Stanger and dubinsky, 1966). The typical cyst is large in size and contains a jelly-like material. Inflammatory cells and peripheral small vesicles invade the surrounding tissue which often form a thick, yellowish and calcified layer.

In the present study gram positive microaerophilous microorganisms were repeatedly isolated from inside the above mentioned kind of cysts. There were subjected to a detailed study.

## MATERIALS AND METHODS

**Cysts** - During a period of five years ending in January , 1981 , ten typical pseudo-alveolar cysts with budding vesicles, containing turbid fluid, were collected from the Tehran abattoir. Fluid was aspirated from the cysts aseptically and cultured on beef heart infusion agar (Difco) . Some of the fluid was centrifuged , and smears were made from the sediment and stained with Gimsa's or Gram's stain. The affected parts of the liver were separated, the vesicles were released onto petri- dishes, and after being washed a few times with normal saline, they were stored in an isotonic solution of + 4°C for the later study.

**Histoslide** - Serial sections prepared from lesioned tissues, fixed in 10% formalin, were stained with hematoxylin and eosin.

**Identification** - The media used for the identification of micro - organisms were beef heart infusion (Difco), Actinomyces broth (BBL) and thioglycollate broth (Difco). The basic medium for fermentation tests consisted of peptone water containing beef extract (0.5%), bacto peptone (1%), NaCl (0.5%), with bromo - thymol blue added as the indicator. The desired carbohydrates were added to give a final concentration of 1.0%. Catalase production was determined by adding a drop of 3% H<sub>2</sub>O<sub>2</sub> to colonies on BHI plates or by adding a drop of 3% H<sub>2</sub>O<sub>2</sub> to a heavy suspension of organism on a microscope slide. Gelatin, MR - VP (BBL) medium, triple sugar Iron (TSI) agar, nitrate agar, tryptophane broth, Simmon's citrate agar, were used for gelatin liquefaction, voges-proskauer and methyl-red reaction , H<sub>2</sub>S production, nitrite, Indole and citrate formation tests, respectively .

## RESULTS

The whole cyst varied from 5 to 25 cm. in diameter ( Fig. 1/2 ) and the vesicles ranged 2 to 8 mm, in diameter (Fig. 2) Cysts were loosely attached to the

surrounding tissues . On the cut surface it was possible to separate cysts from tissues by gentle pressure . Under a dissecting microscope some small budding cysts could be noticed. These remained attached to the main cysts even after standing in isotonic fluid for several days.

The vesicular fluid was yellow with a granular appearance. The micro - organisms were isolated from all the pseudo alveolar cysts collected, except one in which contaminated **Proteus. Spp** filled the whole media. Stained smears of cysts material from one of the cases showed tangled masses of branching filamentous and very fine mycelia. Histological sections showed an impaired germinal layer, without protoscolex, and a folded laminated layer surrounded by epithelioid and giant cells. No vascularization was seen but many necrotic areas were observed around the cysts. Accumulated inflammatory cells in necrotic areas were mainly monocytes and eosinophils.

The lesions were those of characteristic chronic inflammatory reaction. In some sections from the ruptured cysts typical sulfur granules with clubs on the edge of mycelia were observed (Fig. 3) . In experimentally infected guinea pigs, with isolated microorganism the lesion in the liver showed typical granulas with mycelium in the fringes which were surrounded with inflammatory cells (Fig. 4,5).

The colonies on BHI medium with blood (anaerobic) were white, raised, rough and dry, 1mm. or less on diameter. On thioglycollate broth the microorganism produced a granular or «bread-crumbs» type of growth (Fig. 6).

The organisms filamentous, gram positive, nonacid- fast and nonmotile. They showed true branching and broke up into bacillary and coccoid forms. Unevenly stained diphtheroidal forms of varying lengths, knobbed ends and V and Y shaped were also observed (Fig 7). The observed physiologic characteristics were as follows catalase O, sucrose A, maltose A, glucose A, Lactose A, manitol O, Salicin O, Litmus milk, A, gelatin hydrolysis O, Voges - Proskauer test O, methyle - red test nitrate + , H<sub>2</sub>S production O, Citrate O, indole O .

## DISCUSSION

The micro-organism, isolated from the cysts belong to Actinomycetales, a biologically interesting group. This is the order that contains species which produce agents active against other bacterial and fungal infections.

Even members of the order may be active against each other, e. g., the effect of streptomycin produced by **Streptomyces griseus** against **Mycobacterium** (sykes, skinner, 1973).

Different species of **Actinomyces** have been reported from the oral cavity of mammals (posenbunrg, et al 1944), nevertheless, they have been isolated from pathological materials as well as from blood, (coleman et al. 1969).

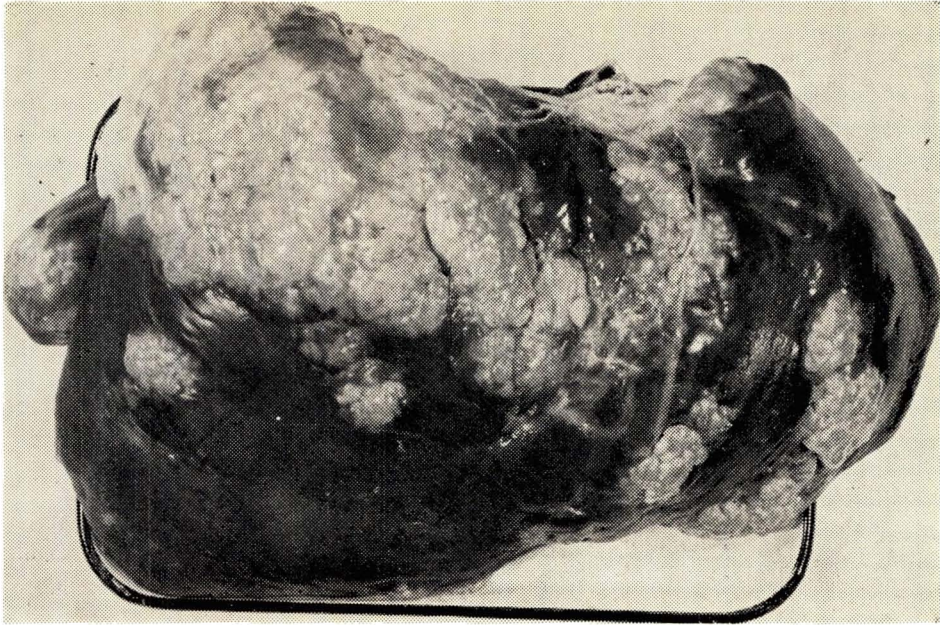
Brown and Von Lichtenberg 1970 , suggested that infection of various sites in the body by blood-borne , organisms, originated from the mouth, is a reasonable possibility. Damage to a tissue or reduced blood supply may provide a niche for **Actinomyces** growth. Since the intact cyst, presumably is resistant to these micro - organisms. They probably invade the old or ruptured cysts.

Due to repeated isolation of the same micro-organism from the cysts it was surmised that the long association of the microorganism with old or ruptured cysts may be the cause of the abnormal growth.

Such cysts could be well occur in the human. Careful study of alveolar cyst cases, therefore, would be of interest since many of these cases have been reported in various places outside the natural distribution areas of **E. multilocularis**, ( cameron 1960 ), Also, not many of these reported cases have been seared to adult **E. multi locularis** as shown by Rausch and Wilson, 1973 .

### **Acknowledgment**

The authors are indebted to Dr. A. H. Ester-Abadi, the chairman of the microbiology Department of the Razi Institute, till 1980, for his valuable advice during the course of this study.



(Fig. (1) Pseudo-alveolar hydatid cyst in cattle liver.

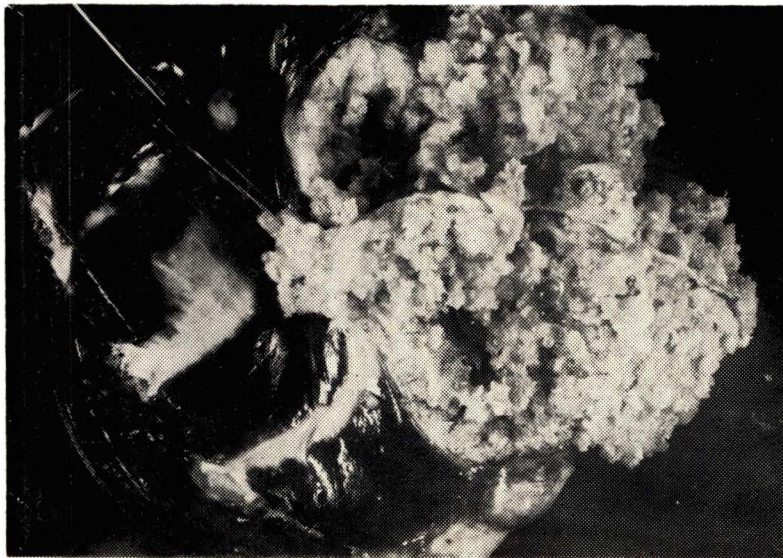


Fig. (2) Cross section of Pseudo-alveolar hydatid cysts in cattle liver.



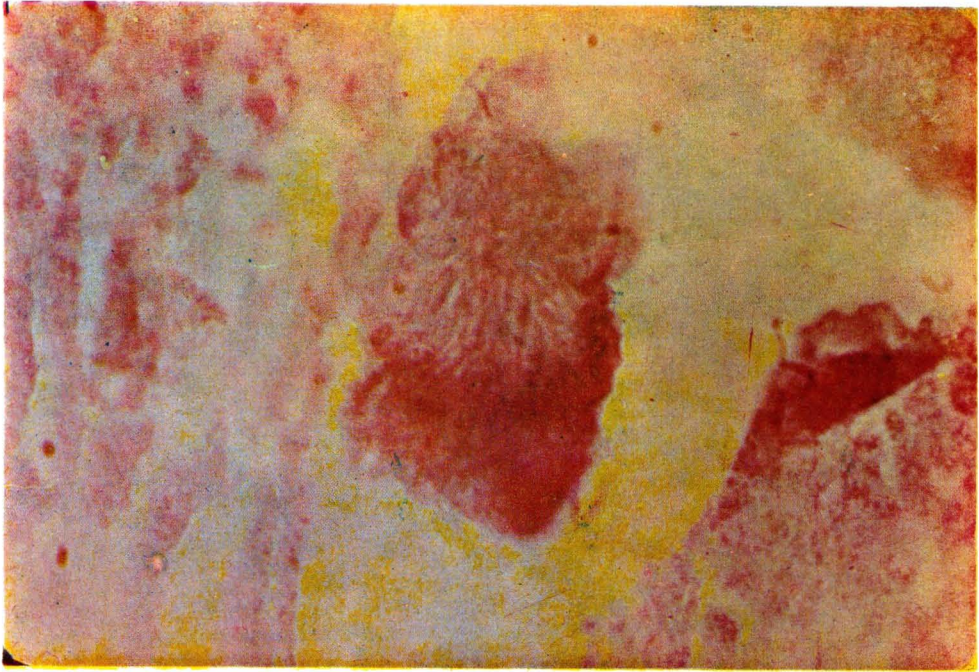

Fig. (3) Sulfur granule in ruptured pseudo-alveolar hydatid cyst. X1250

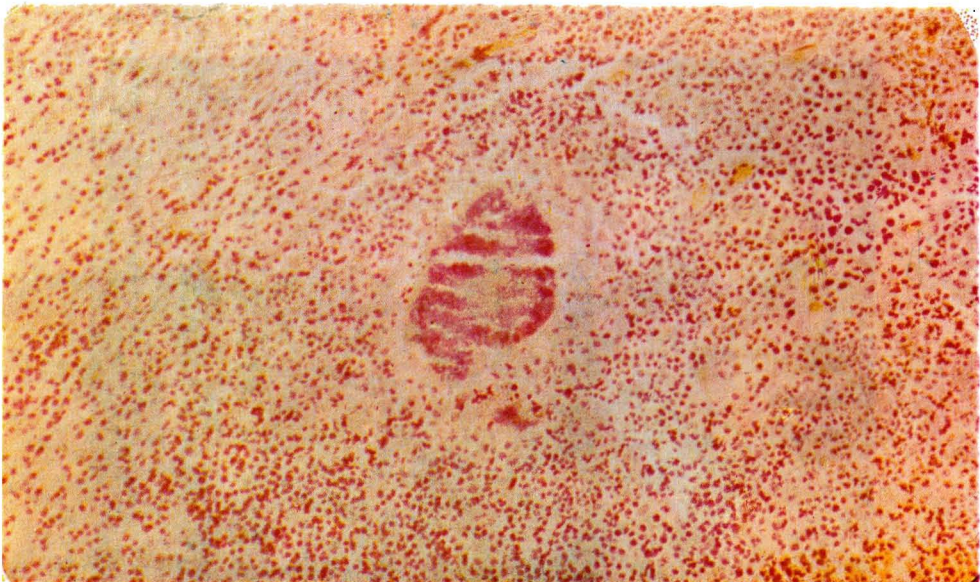


Fig. (4) Lesion from the liver of experimentally infected guinea pig shows typical actinomycetes granules and inflammatory cells X125.



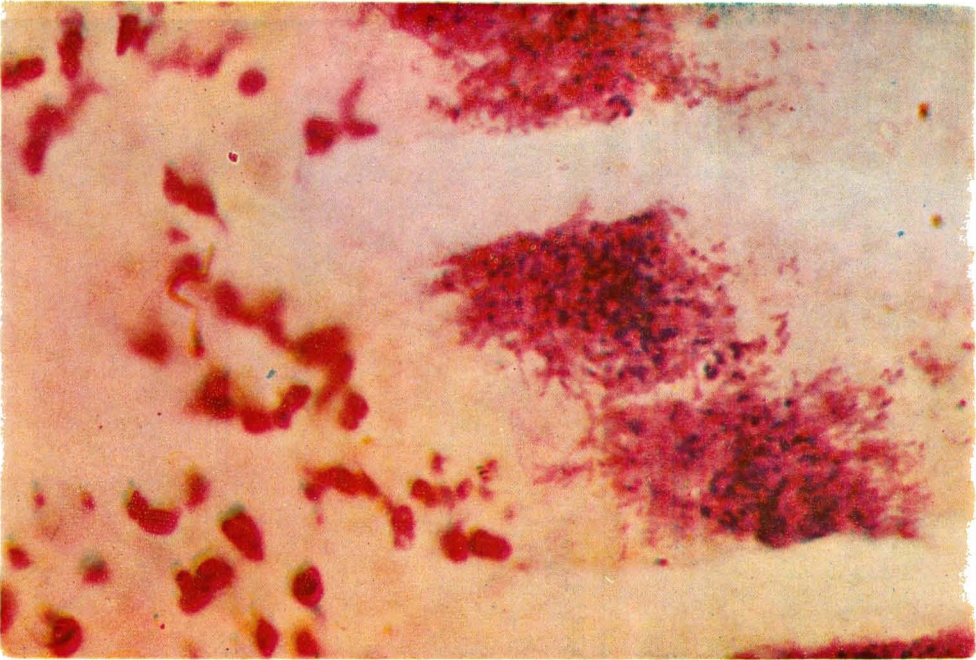


Fig. (5) Lesion from the liver of experimental infected guinea pig shows mycelium in the fringes of granule with inflammatory cells. X 1250.

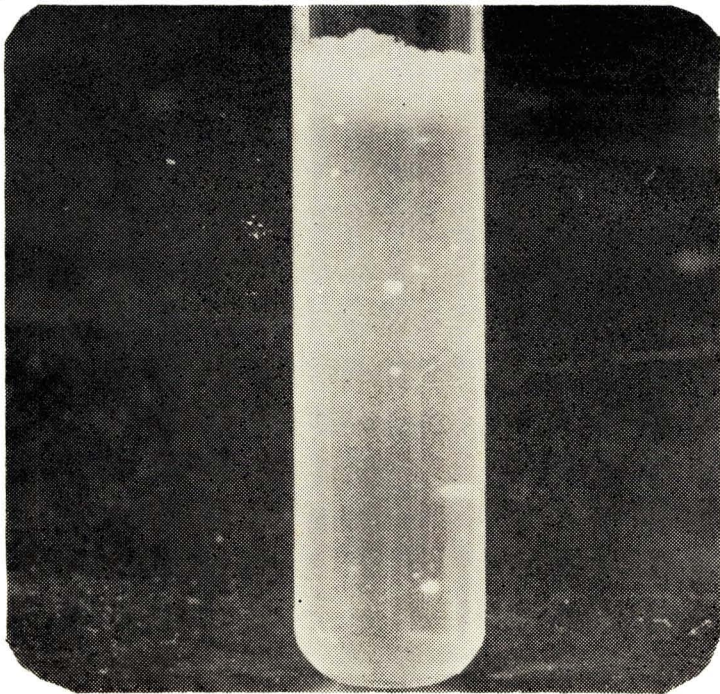


Fig. (6) Actinomyces-bovis isolated from pseudo-alveolar hydatid cyst in thioglycolate agar.

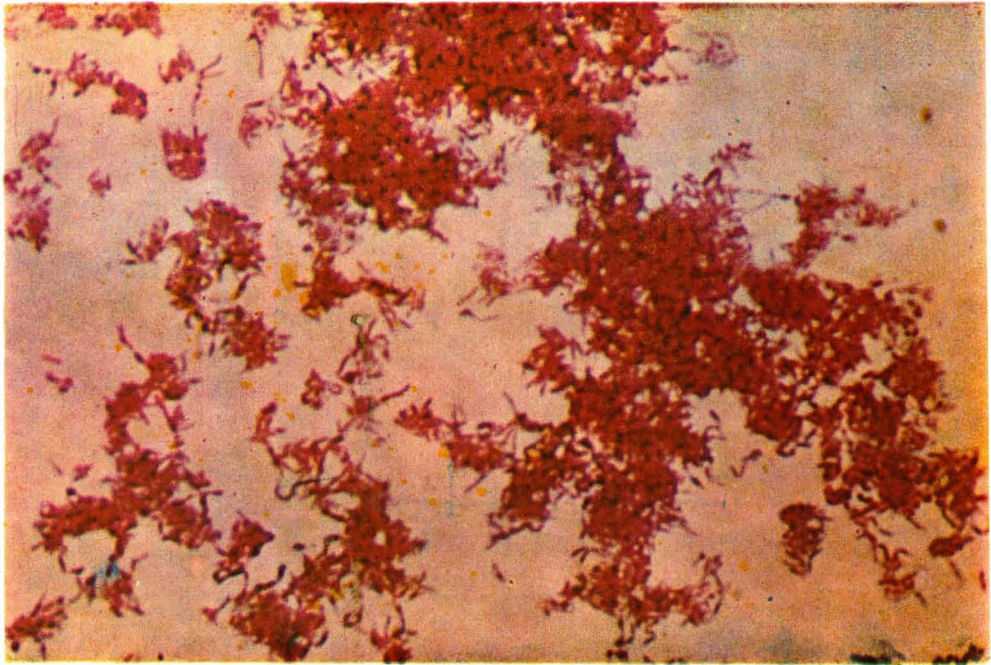


Fig. (7) *Actinomyces bovis*. from thioglycollate agar. X 1250.



## REFERENCES

- Afshar, A., Amri, A. Sabai, M., Naghshineh, R. 1969. Cysts resembling *Echinococcus multilocularis* cysts in a cow in Iran. *Ann. trop. Med. parasite.* 63 (4). 499.
- Brown, J.R. Von Lichtenberg, F. 1970. Experimental actinomycosis in mice. *Arch. Path.* 90, 391-402.
- Cameron, T.W.M. 1960. The incidence and diagnosis of hydatid cyst in Canada *Echinococcus granulosus* Var. *Canadensis. Parasitologia* 2:317-80.
- Cameron, T.W.M., Webster, G.A., 1961. Human multilocular and alveolar Hydatid. *J. Parasitol.* 48 (2) sec. 2, 45-46.
- Coleman, R.M. George, L.K., Rozzell, A.R. 1969. *Actinomyces naeslundii* as an agent of human Actinomycosis. *Appl. Microbiol.* 18, 420-426.
- Gorina, N.S. 1960. Do farm animals play a part in the life cycle of *Echinococcus multilocularis*. *Tezisi Dokl, Mauchnoi Konf. Vses. Obshch. Gelm. Moscow*; Dec. 15-20. pp. 35-37.
- Kurashvili, B.E., Gurchiani, K.R. 1965. Susceptibility of farm animals to alveolar hydatid. *Soobsheh. Akad. Nauk Grus. SSR.* 39 (1), 183-189.
- Magath, T.B., 1965, *Echinococcus multilocularis* in a beef cow from the Middle West. *Science*, 147:632.
- Posenburg, T., Epps, L.J. and Clark. A.R. 1944. A study of the isolation cultivation and pathogenicity of *Actinomyces Israeli* recovered from the human mouth and from Actinomycosis in man. *J. Infect. Dis.* 74, 131-149.
- Rausch, P.L. 1967. A Consideration of Intraspecific categories in the genus *Echinococcus* Rudolphi, 1801 (Gestoda: Taeniidae). *J. Parasitol.* 53:484-491.
- Rausch, P.L., Nelsoh, G.S. 1963. Review of the genus *Echinococcus* Rudolphi, 1801. *Ann. Trop. Med. Parasit.* 57: 127-35.
- Rausch, P.L., Wilson; J.F. 1973. Rearing the adult *Echinococcus multilocularis*. Leuckart, 1863. From sterile larve from man. *Am. J. Trop. Med. & Hyg.* 22: 357-366.
- Sadikov, V.M. 1967. *Echinococcus multilocularis* in the Uzbek SSR. *Zool. Zn.*, 46(3), 331-337.
- Safronov, M.G. 1963. Epizootiology of Unilocular and multiocular hydatid disease in Yakat A.S.S.R. *Veterinariya*, 40 (4), 48-49.
- Schults, R.S. 1962. On the epidemiology of *Echinococcus* and methods of its control. *Med. Parasit. Moscow.* 31, 272.
- Senk, L., Brglez. J., 1966. Nalaz hidatidoze *Echinococcus multilocularis* veterinarium Kod goveda. *Vet. Glasn.*, 20 (6), 320-429.
- Stranger, N., Lubinsky, G. 1966. Vegetative strain of Larval *Echinococcus multilocularis* and domestic herbivores. *Canad. J. Zool.* 44, 494.
- Sykes, G., Skinner, F.A. 1973. Actinomycetales characteristics and practical importance. The society for Applied Bacteriology Syposium series No2, Academic Press., pp. 339.
- Vogel, H. 1957. Studies on the *Echinococcus Multilocularis* of South Germany. *Z. Tropenmed. Parasitol.* 8 (3), 404-456.